What is new in the treatment of interstitial lung diseases

Vasilina Sotiropoulou[1], Theodoros Karampitsakos[1], Matthaios Katsaras[1], Ourania Papaioannou[1], Panagiota Tsiri[1], Fotios Sampsonas[1], Argyrios Tzouvelekis[1]

ABSTRACT

Interstitial lung diseases (ILDs) comprise an heterogenous group of more than 200 pulmonary disorders characterized by lung architectural distortion, with variable amount of fibrotic and/or inflammatory lesions, and associated with significant morbidity and mortality. Pharmacological management is driven by lumping ILDs according to the presumptive predominant pathogenic mechanism, although the coexistence of inflammation and fibrosis may be challenging. In inflammation-predominant diseases, corticosteroids and immunomodulatory agents are the mainstay of treatment. Antifibrotics were initially launched in idiopathic pulmonary fibrosis (IPF). Recently, the concept of progressive pulmonary fibrosis (PPF) has been coined to describe fibrotic lung diseases other than IPF that develop, within a period of 1 year, a progressive disease behavior. The use of antifibrotics may decelerate PPF worsening, similar to their beneficial effects on IPF, and treatment with nintedanib is suggested in patients with PFF, when standard management for fibrotic ILD has failed. Despite the development of novel pharmacological agents and the establishment of non-pharmacological interventions with promising therapeutic potential, in clinical practice, the decisions regarding the management of patients with ILDs still remain highly complex. The integration of individually tailored therapeutic regimens as dictated by personalized medicine approaches is of paramount importance.

AFFILIATION

1 Department of Respiratory Medicine, University Hospital of Patras, Patras, Greece

CORRESPONDENCE TO

Argyrios Tzouvelekis. Department of Respiratory Medicine, University Hospital of Patras, 26504, Rion, Achaia Patras, Greece. E-mail: atzouvelekis@upatras.gr

KEYWORDS

interstitial lung disease, progressive pulmonary fibrosis, nintedanib, pirfenidone, hypersensitivity pneumonitis, connective tissue disease-ILDs

Received: 10 October 2022
Revised: 4 January 2023
Accepted: 4 April 2023

INTRODUCTION

Interstitial lung diseases (ILDs) comprise an heterogenous group of more than 200 lung disorders characterized by variable amount of fibrotic and/or inflammatory lesions[1]. The pathogenesis, diagnosis, classification and treatment of ILDs still present a major challenge for clinicians and researchers, due to their appreciable heterogeneity among individuals and their overlapping clinical presentation and radiological patterns. Erroneous radiologic interpretation and delay in management have been associated with significant morbidity and mortality[1,2].

An aberrant repair process leading to inflammation and fibrosis with enhanced deposition of collagen in the pulmonary parenchyma is the hallmark of ILD pathogenesis[3]. The cumulative damage to the pulmonary epithelium results in epithelial cell apoptosis, fibroblast activation and transforming growth factor-beta (TGF-β)-mediated differentiation to myofibroblasts and extracellular matrix remodeling. The aforementioned lead to lung parenchymal destruction and potentially permanent functional impairment[4]. Although the precise mechanisms have not been fully elucidated, the exposome and the genome of each individual seem to have a cardinal role in a 'multiple-hits' pathogenic process[4].

Given the progressive nature of these disease entities, early diagnosis is of great importance in order to ensure timely therapeutic intervention and slowdown of disease progression[5]. Diagnostic workout hinges on thorough clinical evaluation, high-resolution computed tomography (HRCT), pulmonary function testing, laboratory blood testing including serology testing, and importantly multidisciplinary discussion[1,2]. Current ILD classifications are based on the etiological factors, morphological characteristics and natural history of each disease entity, and patients may be simultaneously classified in more than one category[5]. Interestingly, diagnosis can be modified over time and sometimes a working diagnosis approach is set in case all potential diagnoses are managed with the same treatment regimen[5]. The aim of this article is to present developments in the current pharmacological therapies of ILDs and to highlight novel molecular targets and ongoing research trials that may significantly change the prognosis of this group of diseases in the future.

DEVELOPMENTS

Despite extensive research efforts to date, management of ILDs remains challenging. During the last years, the emergence of treatment guidelines[6] represented a major step towards attenuating confusion in the field; yet, well-designed trials for novel compounds are still needed[6,7].

Published by European Publishing. © 2023 Sotiropoulou V. et al. This is an Open Access article distributed under the terms of the Creative Commons Attribution NonCommercial 4.0 International License. (http://creativecommons.org/licenses/by-nc/4.0)

Pneumon 2023;36(2):14
https://doi.org/10.18332/pne/161867

The most promising treatment options and experimental pharmacotherapies for ILDs are presented in Table 1.

To this end, the two main treatment regimens in the context of ILDs are anti-inflammatory and antifibrotic compounds. Pharmacological management is driven by lumping ILDs according to the presumptive predominant pathogenic mechanism, although the coexistence of inflammation and fibrosis may be challenging[8].

In patients with ILDs and radiologic predominance of inflammatory abnormalities, such as those with connective tissue diseases (CTD-ILDs), hypersensitivity pneumonitis (HP) or non-specific interstitial pneumonia (NSIP), corticosteroids and steroid sparing agents are the mainstay of treatment[8-10]. However, some patients with stable disease and minor clinical findings, can be closely monitored without receiving any treatment[8].

Antifibrotics were initially launched in IPF[11]. However, the term 'progressive pulmonary fibrosis' (PPF) has been recently coined to describe fibrotic lung diseases, other than IPF, that develop into a progressive disease phenotype

Table 1. Treatment options and experimental pharmacotherapies for ILDs

ILD	Treatment options	Status/Evidence	References
IPF	Nintedanib	FDA approved	1
	Pirfenidone	FDA approved	1
	Recombinant human pentraxin 2 (rhPTX-2; PRM-151)	Phase 3 Terminated due to futility NCT04552899 NCT04594707	2
	Pamrevlumab (FG-3019)	Phase 3 Recruiting NCT03955146 NCT04419558	3
	Autotaxin inhibitor (Ziritaxestat)	Phase 3 Completed NCT03733444 NCT03711162	4
	PDE4B inhibitor (BI 1015550)	Phase 2 Completed NCT04419506	5
	Anti-androgen (Danazol)	Phase 2 Recruiting NCT04638517 TELOSCOPE study	6
	TD139-Gal-3 inhibitor	Phase 2 Recruiting NCT03832946	7
	BMS-986278-LPAR1 inhibitor	Phase 2 Recruiting NCT04308681	8
	Saracatinib	Phase 1b/2a Recruiting NCT04598919	9
	Senolytics (Dasatinib plus Quercetin)	Phase 1 Completed NCT02874989	10
	Autologous lung stem cells	Phase 1 Recruiting NCT04262167 NCT02745184	10
	tRNA synthetase inhibitor	Phase 1 Recruiting NCT03711162 NCT04888715	10
	TRK-250-TGFβ1 suppression (inhaled)	Phase 1 Recruiting NCT03727802	10
SSc-ILD	CYC	EULAR recommendation	11
	MMF	Scleroderma Lung Study II	12 and 13
	Nintedanib	Phase 3 completed NCT02597933	14
RA-ILD	Rituximab	EULAR recommendation ACR recommendation	15 and 16
	Tofacitinib – Janus kinase inhibitor vs MTX	Phase 4 Recruiting NCT04311567	10 and 17
IIMs	ICS (pulses) (1st option)	Case series and retrospective studies	18 and 19
	Rituximab or CYC (2nd option)		20
	MMF or AZA (maintenance)		
	CYC and AZA	Phase 3 Recruiting NCT03770663	10
HP	Antigen avoidance	Observational studies	21
Acute	Self-limiting	Observational studies	21
Chronic non-fibrotic	Corticosteroids	Weak evidence	21
Chronic fibrotic	Pirfenidone	Phase 3 Completed NCT02958917	22
PPF	Nintedanib	Phase 3 completed NCT02999178 (INBUILD study)	23
	Pirfenidone + ongoing treatment	Phase 3 completed DRKS00009822	24

ILD: interstitial lung disease. IPF: idiopathic pulmonary fibrosis. SSc: systematic sclerosis. CYC: cyclophosphamide. MMF: mycophenolate mofetil. Gal: galectin. LPAR1: lysophosphatidic acid receptor 1 antagonist. TGF-β1: transforming growth factor-β1. RA: rheumatoid arthritis. EULAR: European league against rheumatism. ACR: American college of rheumatology. IIMs: idiopathic inflammatory myopathies. ICS: intravenous corticosteroids. MTX: methotrexate. ICS: intravenous corticosteroids. AZA: azathioprine. HP: hypersensitivity pneumonitis. PPF: progressive pulmonary fibrosis.

within a period of 1 year, as defined by clinical, functional and/or radiological parameters[6,12]. PPF is a descriptive term applied to any fibrotic ILD diagnosis including patients with CTD-ILD, idiopathic NSIP, sarcoidosis, hypersensitivity pneumonitis, occupational ILD and those with otherwise unclassifiable disease[6]. Based on the fact that pulmonary fibrosis is an end stage situation requiring therapy to hinder disease progression, there has been much interest in whether antifibrotics could be beneficial in PPF[6,12].

Idiopathic pulmonary fibrosis

IPF represents a chronic, debilitating and ultimately lethal ILD of unknown origin occurring primarily in older adults, with a highly variable and heterogeneous disease course[6,13]; yet, the survival has been dramatically improved (almost doubled) with the application of current anti-fibrotic agents. IPF typically affects individuals aged ≥60 years, with most common symptoms being unexplained insidiously worsening dyspnea and dry cough, velcro-type crackles bilaterally and finger clubbing, in the absence of signs and symptoms suggestive of a systemic disease[2]. Usual interstitial pneumonia (UIP) is the histopathologic and radiologic hallmark of the disease[2].

Despite extensive research efforts, no curative drug therapies are available. Pirfenidone and nintedanib are beneficial in patients with IPF, as they decelerate the rate of decline in forced vital capacity (FVC)[6,13]. Nintedanib, originally designed as an anti-cancer drug, is a tyrosine kinase inhibitor that binds to several growth factor receptors, resulting in attenuation of neo-angiogenesis and inhibition of several pro-fibrotic effects[14]. In INPULSIS 1 and 2 phase 3 clinical studies, treatment with nintedanib significantly reduced the rate of FVC decline and, therefore, intercepted disease progression over 52 weeks, in comparison with the placebo arm[15]. Moreover, nintedanib is associated with delayed occurrence of the first acute exacerbation of the disease[15]. The most frequently reported adverse reaction of nintedanib is gastrointestinal intolerance and specifically diarrhea, which in most cases is manageable[15]. Pirfenidone is a synthetic pyridine that inhibits fibrotic, inflammatory and oxidation pathways, through downregulation of inflammatory cytokines and pro-fibrotic factors, including TGF-β and tumor necrosis factor-a (TNF-a)[11]. Four phase 3 trials demonstrated that pirfenidone decelerates the decline in functional indices of patients with IPF. Moreover, meta-analyses showed a decrease in mortality rates in patients with IPF treated with pirfenidone[16,17]. Adverse effects of pirfenidone include skin reactions, such as rash and photosensitivity and gastrointestinal disorders, which can be reversed if drug dose adjustment or short-term treatment interruption is applied[16,17]. To date, the combination of pirfenidone and nintedanib, or their co-administration with other non-antifibrotic agents, has not demonstrated further beneficial effects[18,19].

With regard to corticosteroids in IPF, their use is strongly discouraged, either as single-agents, or in combination with other anti-inflammatory agents[13]. Other repurposed drugs proven ineffective or harmful in IPF are endothelin receptor antagonists, interferon gamma, imatinib, everolimus, warfarin and antacids[6,13].

Connective tissue disease-ILDs

Except from solely pulmonary entities, ILDs may present as manifestations of autoimmune and connective tissue diseases[20]. Patients who present with interstitial pneumonia and characteristics of autoimmunity, without a definite diagnosis of a CTD, are classified as interstitial pneumonia with autoimmune features[21].

ILD is a main cause of mortality in patients with systemic sclerosis (SSc) and the extent of fibrosis on the HRCT is a major predictive factor of disease mortality[7]. The latest recommendations for SSc-ILD suggest that cyclophosphamide is implemented in case of disease progression, while mycophenolate mofetil (MMF) use is neither recommended nor discouraged[7]. However, treatment algorithms according to experts suggest either MMF or cyclophosphamide as agents of choice for induction treatment and MMF for maintenance treatment[22]. In a randomized trial, MMF presented better toxicity profile and fewer premature treatment withdrawals, as cyclophosphamide has been associated with potential risk of myelosuppression, gonadal and urinary tract toxicity[23]. In cases of SSc with life-threatening organ involvement, autologous hematopoietic stem cell transplantation is recommended, only in an individualized benefit and risk assessment context[7].

A considerable proportion of patients with RA presents with perceptible ILD manifestations throughout their life and the overexpression of mucin 5B has been associated with higher risk[24]. Patients with severe or moderate to severe active RA and inadequate response to TNF-α antagonist therapy are treated with rituximab in combination with methotrexate[25,26]. No specific treatment for RA-ILD has been suggested yet. Recently published data from the INBUILD[27] and SENSCIS – a cohort of patients with SSc-ILDs – trials showed that nintedanib might be efficacious for patients with CTD-ILDs including RA-ILDs and SSc-ILDs, as it reduced FVC decline; yet, nintedanib was not beneficial for other features of the SSc clinical spectrum[28]. Finally, the TRAIL 1 study aimed to compare pirfenidone and placebo in patients with RA-ILD. This study seemed to be severely hampered by COVID-19. The primary outcome was not met; yet, patients on the pirfenidone arm presented with a slower decline in FVC. Treatment-related side effects were comparable to other trials[29]. However, findings must be interpreted cautiously.

ILD is the most severe extra-muscular involvement of the diverse group of idiopathic inflammatory myopathies (IIMs) that is often characterized by the NSIP pattern in histopathology and imaging[30]. Occasionally, IIM-related ILDs are associated with rapidly progressive respiratory failure

presenting as acute respiratory distress syndrome and diffuse alveolar damage[30]. The presence of myositis-specific autoantibodies may be closely linked to distinct phenotypic characteristics in IIM-related ILDs and may also be decisive for prognosis and treatment[30]. Anti-aminoacyl-tRNA-synthetase antibody appears to be a favorable prognostic factor, associated with a good response to corticosteroid treatment[31], while anti-melanoma differentiation-associated gene-5 antibody is frequently related to high mortality rates, due to rapidly progressive and immunosuppression-refractory disease[32]. Corticosteroids as monotherapy or combined with anti-inflammatory compounds are considered to be the cornerstone of treatment for ILD associated with IIMs[33]. Patients with acute or subacute form, defined as respiratory deterioration within 3 months, are typically treated with intravenous pulses of methylprednisolone and subsequent high doses of oral prednisolone[34] while cyclophosphamide and rituximab are second-line therapeutic options for refractory cases[35,36]. Given the disease recurrence, long-term maintenance therapy is indispensable and MMF or azathioprine are the pharmacological agents of choice[37].

Hypersensitivity pneumonitis

HP represents a potentially fatal ILD, caused by multiple environmental inhaled antigens triggering exaggerated immunological reactions in susceptible hosts and resulting in inflammation, granulomas and, in some cases, fibrotic lesions[38,39]. Recent guidelines have subclassified HP as fibrotic and non-fibrotic, a notion with important prognostic and treatment implications[39]. The key HRCT features of non-fibrotic HP are parenchymal abnormalities and small airway disease, including ground-glass opacities, poorly defined centrilobular nodules and mosaic attenuation or air-trapping[40]. Typical features of fibrotic HP include traction bronchiectasis, coarse reticulation and volume loss, with or without honeycombing. The coexistence of the aforementioned with mosaic attenuation and diffuse axial distribution differentiate HP from other fibrosing ILDs[40].

Given the lack of an established treatment algorithm, therapeutic management of HP is usually based on patient's clinical features and disease phenotype. The cornerstone of HP treatment is complete avoidance of the causative agent, if identified, in order to prevent disease progression[38]. If so, most cases of acute HP have a self-limiting course, but a close patient monitoring needs to be ensured[38,41]. In cases of non-fibrotic HP with features suggestive of persistent active inflammation, corticosteroids and other immunosuppressants should be considered, when important deterioration of pulmonary functional markers or disease progression are present[38,41]. Fibrotic HP is more likely to respond to antifibrotics and nintedanib has recently been shown to be beneficial in HP when presenting as PPF[6,38].

Progressive pulmonary fibrosis

A substantial proportion of patients with several ILDs including HP, RA-ILD and SSc-ILD presents with progressive phenotype. This entity was denominated 'progressive fibrotic ILDs', however the new guidelines introduced the term PPF[6]. The definition of PPF integrates fibrotic ILDs, excluding IPF, that worsen in at least two of the following: respiratory symptoms, functional indices or radiological findings, in twelve months with no alternative explanation[6,12]. Physiological evidence of disease deterioration includes an absolute change of at least -5 with regard to FVC% predicted or at least -10 to DLCO% predicted within 1 year of follow-up[6,12]. These specific thresholds mainly aim to homogenize patients enrolled in clinical trials. New fibrotic changes, such as irregular reticulation, ground glass opacities, traction bronchiectasis, honeycombing and volume loss must be present in HRCT in order to meet the radiological criteria[6,12].

Based on the hypothesis that the use of antifibrotics may decelerate PPF worsening, similar to their beneficial effects on IPF, several clinical trials were introduced in order to assess the possible effectiveness of pirfenidone and nintedanib in progressive fibrosis. The INBUILD trial showed that patients with progressive fibrosis under nintedanib treatment had a nearly 50% slower decline in FVC over one year compared to placebo[27]. The SENSCIS study reported that nintedanib decreased the rate of FVC decline and the subsequent disease progression in patients with SSc-ILD, although it seemed to have a limited role in other manifestations of SSc[28]. Furthermore, the concomitant use of MMF and nintedanib presented with a good safety profile, with no difference in nintedanib's treatment effect in this subgroup of patients of the SENSCIS study[42]. The RELIEF trial suggested that adding pirfenidone to pre-existing treatment in patients with progressive fibrosis may attenuate disease progression, compared to the placebo group[43]. Of note, RELIEF trial was prematurely terminated due to recruitment issues and thus results should be interpreted with caution. According to the results of the INBUILD trial and the new guidelines, treatment with nintedanib is suggested in PFF, when conventional therapies have failed[6,27]. Therapeutic decisions should be individualized, based on treatment-related risk and benefit.

Other management concepts and overall care

Comprehensive ILD management extends beyond pharmacological therapy, as non-pharmacological interventions are also essential. Preventative strategies, such as smoking cessation, influenza, pneumococcal, and COVID-19 vaccination and exposure abatement are important and should be recommended to all patients[44,45]. Patients with severe hypoxemia with symptoms at rest or on exertion should be given oxygen supplementation, as this intervention has a major role in their health-related quality of life[46]. Pulmonary rehabilitation should also be encouraged, as it is highly effective in patients with chronic lung diseases[47].

Proactive assessment and treatment of patient's comorbidities, such as gastro-esophageal reflux, chronic

obstructive pulmonary disease, lung cancer and pulmonary hypertension, can affect disease mortality[48,49]. Pulmonary hypertension is a severe, underdiagnosed comorbidity of ILDs that adversely impacts quality of life and functional status. Recently, the INCREASE study demonstrated that the inhaled prostacyclin analogue treprostinil significantly improves 6-minute walk distance, an indicator of exercise capacity, decreases N-terminal pro b-type natriuretic peptide levels, a biomarker of cardiac dysfunction, and is associated with fewer disease exacerbations in patients with ILD complicated by pulmonary hypertension compared to placebo[50,51].

Given that ILDs are often associated with dramatic restraints in everyday life and survival, palliative care consultation should also be considered timely, with patient-centered interventions[52]. Lung transplantation remains an intervention that increases life expectancy, thus early referral of rapidly progressors or non-responders to available pharmacotherapies is advised[53]. Nonetheless, only a small number of candidates meet the eligibility standards, due to disease-specific challenges, such as advanced age and comorbidities[53].

Future perspectives

Despite the development of pharmacological agents and the establishment of non-pharmacological interventions with promising therapeutic potential, effective treatment of pulmonary fibrosis is still an unmet need. This mainly stems from the fact that a considerable proportion of patients will still develop progression or will present with acute exacerbations. Additionally, one out of four patients will discontinue antifibrotic therapy.

Thus, there is a pressing need for an oncologic approach, with multiple compounds targeting different pathways being administered concomitantly. Current research activity could hopefully broaden the therapeutic horizons of IPF by identifying new pathogenic pathways and potential molecular targets. The main pathophysiologic changes in IPF alveoli and the molecular pathways that current treatment and experimental pharmacotherapies target are shown in Figure 1. Multiple novel agents targeting immune responses or profibrotic processes, such as autologous lung stem cells (NCT04262167, NCT02745184), tRNA synthetase inhibitor (NCT03711162, NCT04888715), TGF-1 suppressor (NCT03727802), lysophosphatidic acid receptor 1 antagonist (NCT04308681), inhaled galectin-3 inhibitor (NCT03832946), nitrogen oxide inhibitors (NCT03865927), serpin peptidase inhibitor (NCT03538301), senolytic combination of dasatinib and quercetin (NCT02874989) are being investigated in clinical trials with promising preliminary results[44]. The synthetic androgen danazol has demonstrated potential effect on short telomere syndromes and a phase 2 clinical trial, aiming to study its effects in pulmonary fibrosis associated with telomeropathies, is currently in process (NCT04638517)[54]. Intravenous infusion of recombinant human pentraxin-2 – a protein that inhibits monocytes' differentiation into macrophages and profibrotic fibrocytes – initially showed promising results[55]; yet, the phase 3 clinical trial was prematurely terminated due to futility (NCT04552899, NCT04594707). Pamrevlumab – a recombinant human monoclonal antibody targeting connective tissue growth factor and acting as a mediator of signal transduction in fibrogenic processes – is also in phase 3 development for IPF (NCT03955146, NCT04419558), given its promising results in tolerability and efficacy in phase 2 trials[56]. GLPG1690 (ziritaxestat), which inhibits autotaxin, an enzyme important for generating lysophosphatidic

Figure 1. The main pathophysiologic changes in IPF alveoli and the molecular pathways that current treatment and experimental pharmacotherapies target

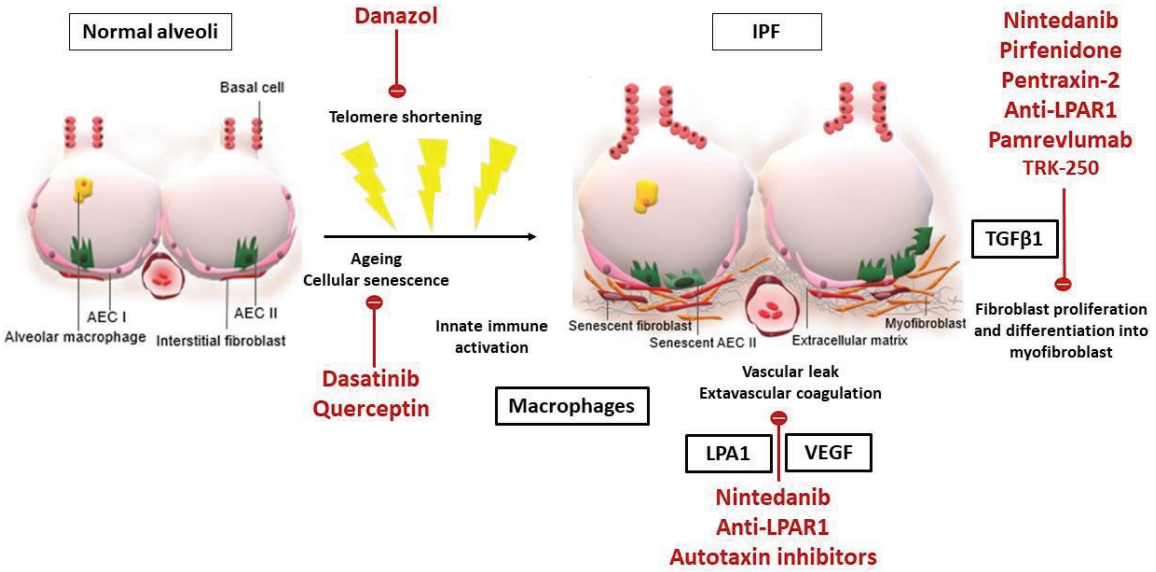

acid, has also demonstrated an encouraging tolerance and effectiveness profile[57], that supports further clinical assessment (NCT03733444, NCT03711162). Additionally, a phase 2 clinical study demonstrated safety and efficacy of a PDE4B inhibitor, BI 1015550, in slowing down functional progression of IPF[58]. Safety profile was acceptable, with diarrhea being the most commonly reported adverse reaction. The most important attribute of the trial was the synergistic effect of PDE4B inhibitor with current standard of care, highlighting the need for an oncologic approach. Efficacy was observed, despite enrolling patients with more progressive disease, indicated by an almost double functional decline in the placebo arm compared to antifibrotic treatment arm (-59.2 mL in 12 weeks) than that reported in the INPULSIS study (-113.6 mL during 52 weeks)[59]. Considering the role of such compounds in preventing COPD exacerbations and progression of lung fibrosis, a potential benefit for individuals with combined pulmonary fibrosis and emphysema should be investigated in the context of future clinical trials. These are consistently excluded from previous randomized clinical trials; yet, they represent almost 25% of IPF cases seen in the everyday clinical practice and deserve attention.

CONCLUSION

The main challenge of trials of novel compounds is the fact that they should be effective as an add-on therapy, given that novel agents cannot be compared to true placebo. This demands a deep insight into pharmacokinetics, pharmacodynamics and drug-drug interactions. The disappointing results of human pentraxin 2 trial is a typical paradigm showing how demanding is the challenge of launching an add-on therapy. Another challenge is whether some compounds including inhaled pirfenidone and thyroid hormone have potential as inhaled therapy, sparing thus systemic adverse events and concomitantly being effective[60,61]. Finally, an important challenge is the identification of compounds able to improve quality of life, except drugs able to slow down FVC decline. The extended-release form of the dual-acting κ opioid receptor agonist/μ opioid receptor antagonist, nalbuphine, has great potential with regard to chronic cough reduction in patients with pulmonary fibrosis[62]. Taken together, integration of individually tailored therapeutic regimens as dictated by personalized medicine approaches is of paramount importance. Reproducible theragnostic biomarkers will hopefully revolutionize the treatment landscape for patients living with ILDs.

CONFLICTS OF INTEREST

The authors have completed and submitted the ICMJE Form for Disclosure of Potential Conflicts of Interest and none was reported.

FUNDING

There was no source of funding for this research.

ETHICAL APPROVAL AND INFORMED CONSENT

Ethical approval and informed consent were not required for this study.

DATA AVAILABILITY

The data supporting this research are available from the authors on reasonable request.

PROVENANCE AND PEER REVIEW

Not commissioned; externally peer reviewed.

REFERENCES

1. Travis WD, Costabel U, Hansell DM, et al. An official American Thoracic Society/European Respiratory Society statement: Update of the international multidisciplinary classification of the idiopathic interstitial pneumonias. Am J Respir Crit Care Med. 2013;188(6):733-748. doi:10.1164/rccm.201308-1483ST
2. Raghu G, Remy-Jardin M, Myers JL, et al. Diagnosis of Idiopathic Pulmonary Fibrosis. An Official ATS/ERS/JRS/ALAT Clinical Practice Guideline. Am J Respir Crit Care Med. 2018;198(5):e44-e68. doi:10.1164/rccm.201807-1255ST
3. Schuliga M, Read J, Knight DA. Ageing mechanisms that contribute to tissue remodeling in lung disease. Ageing Res Rev. 2021;70:101405. doi:10.1016/j.arr.2021.101405
4. Sgalla G, Iovene B, Calvello M, Ori M, Varone F, Richeldi L. Idiopathic pulmonary fibrosis: pathogenesis and management. Respir Res. 2018;19:32. doi:10.1186/s12931-018-0730-2
5. Spagnolo P, Ryerson CJ, Putman R, et al. Early diagnosis of fibrotic interstitial lung disease: challenges and opportunities. Lancet Respir Med. 2021;9(9):1065-1076. doi:10.1016/S2213-2600(21)00017-5
6. Raghu G, Remy-Jardin M, Richeldi L, et al. Idiopathic Pulmonary Fibrosis (an Update) and Progressive Pulmonary Fibrosis in Adults: An Official ATS/ERS/JRS/ALAT Clinical Practice Guideline. Am J Respir Crit Care Med. 2022;205(9):e18-e47. doi:10.1164/rccm.202202-0399ST
7. Kowal-Bielecka O, Fransen J, Avouac J, et al. Update of EULAR recommendations for the treatment of systemic sclerosis. Ann Rheum Dis. 2017;76(8):1327-1339. doi:10.1136/annrheumdis-2016-209909
8. Maher TM, Wuyts W. Management of Fibrosing Interstitial Lung Diseases. Adv Ther. 2019;36(7):1518-1531. doi:10.1007/s12325-019-00992-9
9. Karampitsakos T, Kalogeropoulou C, Tzilas V, et al. Safety and Effectiveness of Mycophenolate Mofetil in Interstitial Lung Diseases: Insights from a Machine Learning Radiographic Model. Respiration. 2022;101(3):262-271. doi:10.1159/000519215
10. Karampitsakos T, Vraka A, Bouros D, Liossis SN, Tzouvelekis A. Biologic Treatments in Interstitial Lung Diseases. Front Med (Lausanne). 2019;6:41. doi:10.3389/fmed.2019.00041
11. Spagnolo P, Kropski JA, Jones MG, et al. Idiopathic pulmonary fibrosis: Disease mechanisms and drug development.

Pharmacol Ther. 2021;222:107798. doi:10.1016/j.pharmthera.2020.107798
12. Tzilas V, Tzouvelekis A, Ryu JH, Bouros D. 2022 update on clinical practice guidelines for idiopathic pulmonary fibrosis and progressive pulmonary fibrosis. Lancet Respir Med. 2022;10(8):729-731. doi:10.1016/S2213-2600(22)00223-5
13. Raghu G, Rochwerg B, Zhang Y, et al. An Official ATS/ERS/JRS/ALAT Clinical Practice Guideline: Treatment of Idiopathic Pulmonary Fibrosis. An Update of the 2011 Clinical Practice Guideline. Am J Respir Crit Care Med. 2015;192(2):e3-e19. doi:10.1164/rccm.201506-1063ST
14. Wollin L, Wex E, Pautsch A, et al. Mode of action of nintedanib in the treatment of idiopathic pulmonary fibrosis. Eur Respir J. 2015;45(5):1434-1445. doi:10.1183/09031936.00174914
15. Richeldi L, du Bois RM, Raghu G, et al. Efficacy and Safety of Nintedanib in Idiopathic Pulmonary Fibrosis. N Engl J Med. 2014;370(22):2071-2082. doi:10.1056/NEJMoa1402584
16. Noble PW, Albera C, Bradford WZ, et al. Pirfenidone for idiopathic pulmonary fibrosis: analysis of pooled data from three multinational phase 3 trials. Eur Respir J. 2016;47(1):243-253. doi:10.1183/13993003.00026-2015
17. Taniguchi H, Ebina M, Kondoh Y, et al. Pirfenidone in idiopathic pulmonary fibrosis. Eur Respir J. 2010;35(4):821-829. doi:10.1183/09031936.00005209
18. Flaherty KR, Fell CD, Huggins JT, et al. Safety of nintedanib added to pirfenidone treatment for idiopathic pulmonary fibrosis. Eur Respir J. 2018;52(2):1800230. doi:10.1183/13993003.00230-2018
19. Vancheri C, Kreuter M, Richeldi L, et al. Nintedanib with Add-on Pirfenidone in Idiopathic Pulmonary Fibrosis. Results of the INJOURNEY Trial. Am J Respir Crit Care Med. 2018;197(3):356-363. doi:10.1164/rccm.201706-1301OC
20. Spagnolo P, Distler O, Ryerson CJ, et al. Mechanisms of progressive fibrosis in connective tissue disease (CTD)-associated interstitial lung diseases (ILDs). Ann Rheum Dis. 2021;80(2):143-150. doi:10.1136/annrheumdis-2020-217230
21. Fischer A, Antoniou KM, Brown KK, et al. An official European Respiratory Society/American Thoracic Society research statement: interstitial pneumonia with autoimmune features. Eur Respir J. 2015;46(4):976-987. doi:10.1183/13993003.00150-2015
22. Fernández-Codina A, Walker KM, Pope JE; Scleroderma Algorithm Group. Treatment Algorithms for Systemic Sclerosis According to Experts. Arthritis Rheumatol. 2018;70(11):1820-1828. doi:10.1002/art.40560
23. Tashkin DP, Roth MD, Clements PJ, et al. Mycophenolate Mofetil versus Oral Cyclophosphamide in Scleroderma-related Interstitial Lung Disease: Scleroderma Lung Study II (SLS-II), a double-blind, parallel group, randomised controlled trial. Lancet Respir Med. 2016;4(9):708-719. doi:10.1016/S2213-2600(16)30152-7
24. Juge PA, Lee JS, Ebstein E, et al. MUC5B Promoter Variant and Rheumatoid Arthritis with Interstitial Lung Disease. N Engl J Med. 2018;379(23):2209-2219. doi:10.1056/NEJMoa1801562
25. Smolen JS, Landewé RBM, Bijlsma JWJ, et al. EULAR recommendations for the management of rheumatoid arthritis with synthetic and biological disease-modifying antirheumatic drugs: 2019 update. Ann Rheum Dis. 2020;79(6):685-699. doi:10.1136/annrheumdis-2019-216655
26. Fraenkel L, Bathon JM, England BR, et al. 2021 American College of Rheumatology Guideline for the Treatment of Rheumatoid Arthritis. Arthritis Care Res (Hoboken). 2021;73(7):924-939. doi:10.1002/acr.24596
27. Flaherty KR, Wells AU, Cottin V, et al. Nintedanib in Progressive Fibrosing Interstitial Lung Diseases. N Engl J Med. 2019;381(18):1718-1727. doi:10.1056/NEJMoa1908681
28. Distler O, Highland KB, Gahlemann M, et al. Nintedanib for Systemic Sclerosis-Associated Interstitial Lung Disease. N Engl J Med. 2019;380(26):2518-2528. doi:10.1056/NEJMoa1903076
29. Solomon JJ, Danoff SK, Woodhead FA, et al. Safety, tolerability, and efficacy of pirfenidone in patients with rheumatoid arthritis-associated interstitial lung disease: a randomised, double-blind, placebo-controlled, phase 2 study. Lancet Respir Med. 2023;11(1): 87-96. doi:10.1016/s2213-2600(22)00260-0
30. Douglas WW, Tazelaar HD, Hartman TE, et al. Polymyositis–Dermatomyositis-associated Interstitial Lung Disease. Am J Respir Crit Care Med. 2001;164(7):1182-1185. doi:10.1164/ajrccm.164.7.2103110
31. Hozumi H, Fujisawa T, Nakashima R, et al. Efficacy of Glucocorticoids and Calcineurin Inhibitors for Anti-aminoacyl-tRNA Synthetase Antibody– positive Polymyositis/dermatomyositis–associated Interstitial Lung Disease: A Propensity Score–matched Analysis. J Rheumatol. 2019;46(5):509-517. doi:10.3899/jrheum.180778
32. Gono T, Kawaguchi Y, Satoh T, et al. Clinical manifestation and prognostic factor in anti-melanoma differentiation-associated gene 5 antibody-associated interstitial lung disease as a complication of dermatomyositis. Rheumatology (Oxford). 2010;49(9):1713-1719. doi:10.1093/rheumatology/keq149
33. Morisset J, Johnson C, Rich E, Collard HR, Lee JS. Management of Myositis-Related Interstitial Lung Disease. Chest. 2016;150(5):1118-1128. doi:10.1016/j.chest.2016.04.007
34. Long K, Danoff SK. Interstitial Lung Disease in Polymyositis and Dermatomyositis. Clin Chest Med. 2019;40(3):561-572. doi:10.1016/j.ccm.2019.05.004
35. Ge Y, Peng Q, Zhang S, Zhou H, Lu X, Wang G. Cyclophosphamide treatment for idiopathic inflammatory myopathies and related interstitial lung disease: a systematic review. Clin Rheumatol. 2015;34(1):99-105. doi:10.1007/s10067-014-2803-z
36. Ge Y, Li S, Tian X, He L, Lu X, Wang G. Anti-melanoma differentiation-associated gene 5 (MDA5) antibody-positive

dermatomyositis responds to rituximab therapy. Clin Rheumatol. 2021;40(6):2311-2317. doi:10.1007/s10067-020-05530-5
37. Huapaya JA, Silhan L, Pinal-Fernandez I, et al. Long-Term Treatment With Azathioprine and Mycophenolate Mofetil for Myositis-Related Interstitial Lung Disease. Chest. 2019;156(5):896-906. doi:10.1016/j.chest.2019.05.023
38. Costabel U, Miyazaki Y, Pardo A, et al. Hypersensitivity pneumonitis. Nat Rev Dis Primers. 2020;6(1):65. doi:10.1038/s41572-020-0191-z
39. Raghu G, Remy-Jardin M, Ryerson CJ, et al. Diagnosis of Hypersensitivity Pneumonitis in Adults. An Official ATS/JRS/ALAT Clinical Practice Guideline. Am J Respir Crit Care Med. 2020;202(3):e36-e69. doi:10.1164/rccm.202005-2032ST
40. Salisbury ML, Gross BH, Chughtai A, et al. Development and validation of a radiological diagnosis model for hypersensitivity pneumonitis. Eur Respir J. 2018;52(2):1800443. doi:10.1183/13993003.00443-2018
41. Hamblin M, Prosch H, Vašáková M. Diagnosis, course and management of hypersensitivity pneumonitis. Eur Respir Rev. 2022;31(163):210169. doi:10.1183/16000617.0169-2021
42. Highland KB, Distler O, Kuwana M, et al. Efficacy and safety of nintedanib in patients with systemic sclerosis-associated interstitial lung disease treated with mycophenolate: a subgroup analysis of the SENSCIS trial. Lancet Respir Med. 2021;9(1):96-106. doi:10.1016/S2213-2600(20)30330-1
43. Behr J, Prasse A, Kreuter M, et al. Pirfenidone in patients with progressive fibrotic interstitial lung diseases other than idiopathic pulmonary fibrosis (RELIEF): a double-blind, randomised, placebo-controlled, phase 2b trial. Lancet Respir Med. 2021;9(5):476-486. doi:10.1016/S2213-2600(20)30554-3
44. Johannson KA, Chaudhuri N, Adegunsoye A, Wolters PJ. Treatment of fibrotic interstitial lung disease: current approaches and future directions. Lancet. 2021;398(10309):1450-1460. doi:10.1016/S0140-6736(21)01826-2
45. Raghu G, Collard HR, Egan JJ, et al. An Official ATS/ERS/JRS/ALAT Statement: Idiopathic Pulmonary Fibrosis: Evidence-based Guidelines for Diagnosis and Management. Am J Respir Crit Care Med. 2011;183(6):788-824. doi:10.1164/rccm.2009-040GL
46. Visca D, Mori L, Tsipouri V, et al. Effect of ambulatory oxygen on quality of life for patients with fibrotic lung disease (AmbOx): a prospective, open-label, mixed-method, crossover randomised controlled trial. Lancet Respir Med. 2018;6(10):759-770. doi:10.1016/S2213-2600(18)30289-3
47. Holland AE, Cox NS, Houchen-Wolloff L, et al. Defining Modern Pulmonary Rehabilitation. An Official American Thoracic Society Workshop Report. Ann Am Thorac Soc. 2021;18(5):e12-e29. doi:10.1513/AnnalsATS.202102-146ST
48. Schwarzkopf L, Witt S, Waelscher J, Polke M, Kreuter M. Associations between comorbidities, their treatment and survival in patients with interstitial lung diseases - a claims data analysis. Respir Res. 2018;19(1):73. doi:10.1186/s12931-018-0769-0
49. Saracatinib in the Treatment of Idiopathic Pulmonary Fibrosis (STOP-IPF). ClinicalTrials.gov. October 22, 2020. Updated February 21, 2023. Accessed January 4, 2023. https://clinicaltrials.gov/ct2/show/study/NCT04598919
50. Waxman A, Restrepo-Jaramillo R, Thenappan T, et al. Inhaled Treprostinil in Pulmonary Hypertension Due to Interstitial Lung Disease. N Engl J Med. 2021;384(4):325-334. doi:10.1056/NEJMoa2008470
51. Nathan SD, Waxman A, Rajagopal S, et al. Inhaled treprostinil and forced vital capacity in patients with interstitial lung disease and associated pulmonary hypertension: a post-hoc analysis of the INCREASE study. Lancet Respir Med. 2021;9(11):1266-1274. doi:10.1016/S2213-2600(21)00165-X
52. Kreuter M, Bendstrup E, Russell AM, et al. Palliative care in interstitial lung disease: living well. Lancet Respir Med. 2017;5(12):968-980. doi:10.1016/S2213-2600(17)30383-1
53. George PM, Patterson CM, Reed AK, Thillai M. Lung transplantation for idiopathic pulmonary fibrosis. Lancet Respir Med. 2019;7(3):271-282. doi:10.1016/S2213-2600(18)30502-2
54. Mackintosh JA, Pietsch M, Lutzky V, et al. TELO-SCOPE study: a randomised, double-blind, placebo-controlled, phase 2 trial of danazol for short telomere related pulmonary fibrosis. BMJ Open Respir Res. 2021;8(1):e001127. doi:10.1136/bmjresp-2021-001127
55. Raghu G, van den Blink B, Hamblin MJ, et al. Effect of Recombinant Human Pentraxin 2 vs Placebo on Change in Forced Vital Capacity in Patients With Idiopathic Pulmonary Fibrosis: A Randomized Clinical Trial. JAMA. 2018;319(22):2299-2307. doi:10.1001/jama.2018.6129
56. Richeldi L, Fernández Pérez ER, Costabel U, et al. Pamrevlumab, an anti-connective tissue growth factor therapy, for idiopathic pulmonary fibrosis (PRAISE): a phase 2, randomised, double-blind, placebo-controlled trial. Lancet Respir Med. 2020;8(1):25-33. doi:10.1016/S2213-2600(19)30262-0
57. Maher TM, van der Aar EM, Van de Steen O, et al. Safety, tolerability, pharmacokinetics, and pharmacodynamics of GLPG1690, a novel autotaxin inhibitor, to treat idiopathic pulmonary fibrosis (FLORA): a phase 2a randomised placebo-controlled trial. Lancet Respir Med. 2018;6(8):627-635. doi:10.1016/S2213-2600(18)30181-4
58. Richeldi L, Azuma A, Cottin V, et al. Trial of a Preferential Phosphodiesterase 4B Inhibitor for Idiopathic Pulmonary Fibrosis. N Engl J Med. 2022;386(23):2178-2187. doi:10.1056/NEJMoa2201737
59. Chambers RC. Preferential PDE4B Inhibition - A Step toward a New Treatment for Idiopathic Pulmonary Fibrosis. N Engl J Med. 2022;386(23):2235-2236. doi:10.1056/NEJMe2205411

60. Yu G, Tzouvelekis A, Wang R, et al. Thyroid hormone inhibits lung fibrosis in mice by improving epithelial mitochondrial function. Nat Med. 2018;24(1):39-49. doi:10.1038/nm.4447
61. Khoo JK, Montgomery AB, Otto KL, et al. A Randomized, Double-Blinded, Placebo-Controlled, Dose-Escalation Phase 1 Study of Aerosolized Pirfenidone Delivered via the PARI Investigational eFlow Nebulizer in Volunteers and Patients with Idiopathic Pulmonary Fibrosis. J Aerosol Med Pulm Drug Deliv. 2020;33(1):15-20. doi:10.1089/jamp.2018.1507
62. A Study of Nalbuphine (Extended Release) ER in Idiopathic Pulmonary Fibrosis (IPF) for Treatment of Cough (CANAL). ClinicalTrials.gov. July 23, 2019. Updated May 17, 2023. Accessed January 4, 2023. https://clinicaltrials.gov/ct2/show/NCT04030026