

Co-existence of endobronchial lipoma and lung adenocarcinoma

Vasiliki Petta¹,
Athanasios Zetos¹,
Danai Bisirtzoglou¹,
Maria Salomidou¹,
Georgios Papias²,
Niki Arnogiannaki²,
Charalambos Marketos¹

¹Respiratory Medicine Department,
General Anticancer Oncology Hospital
of Athens "Agios Savvas"

²Pathology Department,
General Anticancer Oncology Hospital
of Athens "Agios Savvas", Athens, Greece

Key words:

- Bronchoscopy
- Mass
- Lung lipoma
- Biopsy
- Lung adenocarcinoma

Correspondence to:

Vasiliki Petta
Respiratory Medicine Department, General Anticancer
Hospital of Athens "Saint Savvas", Greece
Tel.: +30 6948228586
e-mail: v_petta@hotmail.com

ABSTRACT

Endobronchial lipoma is an infrequent benign tumor originating from adipose tissue, most commonly seen in middle-aged men, with a peak incidence between the fifth and sixth decades of life. Usually, the tumor is found in central airways, in lobar or segmental bronchi, mainly located in the right lung and easily detected during bronchoscopy. The lesion may lead to chronic lung destruction due to bronchial obstruction. Bronchoscopic resection with biopsy forceps is both diagnostic and therapeutic method of choice. Lung cancer is the leading cause of mortality worldwide and is diagnosed in advanced stage, due to lack of specific symptoms. Non-small cell lung cancer (NSCLC) accounts for 80-85% of all cases, with adenocarcinoma being the most common histologic subtype. In this article, we present a rare case of co-existence of endobronchial lipoma located in the right lung and adenocarcinoma located in left lung in a 61-year old smoker, without any symptoms.

Pneumon 2019, 32(3):101-104.

Endobronchial lipoma is an infrequent benign tumor originating from adipose tissue, most commonly seen in middle-aged men, with a peak incidence between the fifth and sixth decades of life. Usually, the tumor is found in central airways, in lobar or segmental bronchi, mainly located in the right lung and easily detected during bronchoscopy. The lesion may lead to chronic lung destruction due to bronchial obstruction. Bronchoscopic resection with biopsy forceps is both diagnostic and therapeutic method of choice. Lung cancer is the leading cause of mortality worldwide and is diagnosed in advanced stage, due to lack of specific symptoms. Non-small cell lung cancer (NSCLC) accounts for 80-85% of all cases, with adenocarcinoma being the most common histologic subtype. In this article, we present a rare case of co-existence of endobronchial lipoma located in the right lung and adenocarcinoma located in left lung in a 61-year old smoker, without any symptoms.

INTRODUCTION:

Endobronchial lipomas are infrequent benign tumors originating from the adipose tissue, with incidence ranging from only 0.1 to 0.5% of all lung tumors¹⁻³. They consist of mature adipose tissue, fibrous components, and normal bronchial epithelium² (figure 3). The tumors are commonly found in the central airways, in lobar or segmental bronchi of the endobronchial tree, mainly located in the right lung, and are easily detected during bronchoscopy, with only a small percentage being located in the periphery of the lung^{2,3}. Smoking and obesity are significant risk factors for the development of endobronchial lipomas.² Macroscopically, all the lesions are seen as well circumscribed, soft, yellow masses ranging in size from 1 to 3cm in the greatest diameter, with a smooth round surface³.

Lung cancer is the most frequent cause of cancer-related deaths worldwide. Every year, 1.8 million people are diagnosed with lung cancer, and 1.6 million people die as a result of the disease. Non-small cell lung cancer is the predominant form of the disease, accounting for approximately 85% of cases⁴. Smoking is well acknowledged as the main risk factor for lung cancer, and is estimated to be responsible for 90% of cases in males and 80% of cases in females. However, over recent decades several changes have taken place in lung cancer epidemiology. Adenocarcinoma, replacing squamous cell cancer, has become the most common morphological type of lung cancer. In addition to smoking, several other risk factors, e.g. second-hand smoke, air pollution, cooking fumes, exposure to indoor radon and comorbidities such as chronic obstructive pulmonary disease (COPD) or previous tuberculosis, have become more widely recognized⁵.

Surgery is the recommended treatment for patients with stage I-II non-small-cell lung cancer (NSCLC). 5-year survival is 77–92% for clinical stage IA, 68% for stage IB, 60% for stage IIA, and 53% for stage IIB. Most patients present with advanced disease at the time of diagnosis and have a poor prognosis, with the vast majority surviving less than 5 years. Although new therapies have been introduced in recent years that target molecular disease drivers present in a subset of patients, there is a significant need for treatments able to improve response and extend survival while minimizing effects on quality of life⁶.

CASE

A 61-year old man, current smoker presented with a shadow pointed out in left upper lobe in chest X-Ray, as an

incidental finding. A contrast enhanced chest computed tomography (CT) revealed a low-density tumor mass of 3.5 cm in maximum diameter, located in the segments 1+2 of left upper lobe, peripherally, in touch with the pleura (Figure 1). Flexible bronchoscopy revealed no endobronchial lesion in left upper lobe as showed in chest CT; however, segment 8 of basal group of right lower lobe was completely occluded by a sub yellow mass, finding that was not revealed in CT scan. The tumor had a round, smooth, shiny surface as found out during the exclusion. The lesion was almost fully resected using needle biopsy (Figure 2). Pathologic examination confirmed endobron-

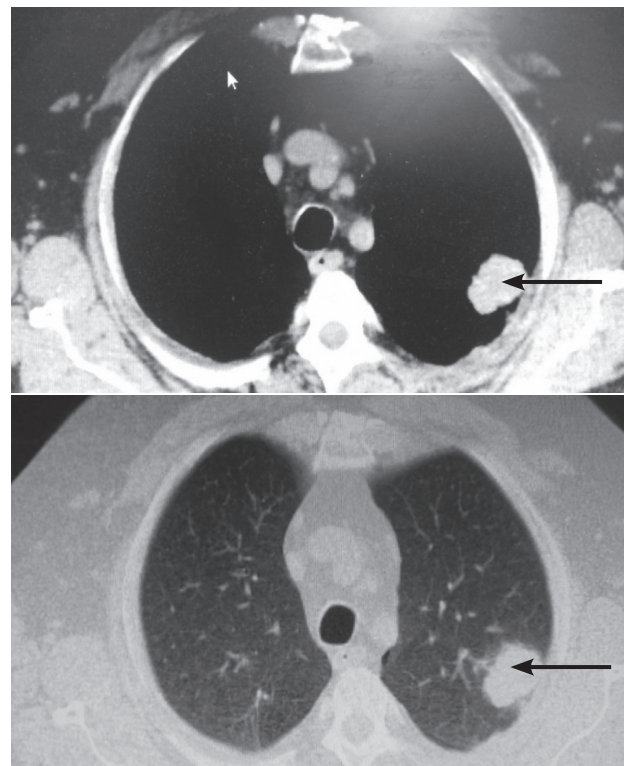


FIGURE 1.

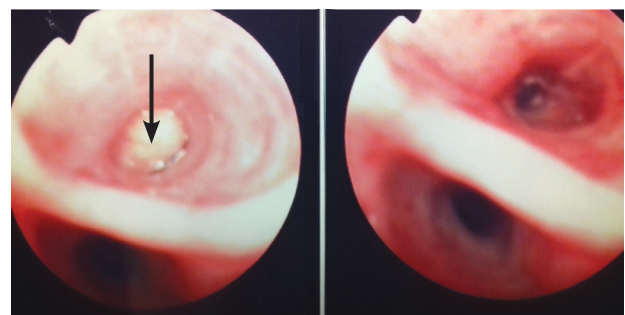


FIGURE 2.

chial lipoma and no evidence of malignancy. The mass was formed by well differentiated adipose tissue. The patient underwent fine needle biopsy (FNB) by chest CT navigation of the lesion in left upper lobe, the histopathology of which revealed lung adenocarcinoma of low differentiation (Figure 3).

DISCUSSION

Endobronchial lipoma is most commonly seen in middle-aged men, with a peak incidence between the fifth and sixth decades of life. Fever, progressive dyspnea, persistent cough, sputum production, hemoptysis, wheezing, stridor, recurrent pneumonia, due to partial or total bronchial obstruction and secondary lung parenchyma destruction caused by the tumor, are common clinical

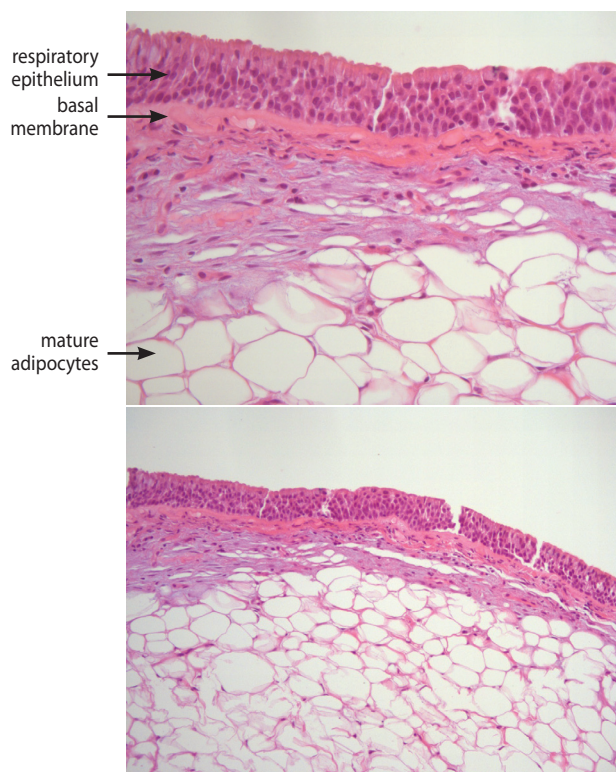


FIGURE 3.

features of presentation^{1,3,8}. The slow tumoral growth is the reason for late manifestation of symptoms, ranging from a few months to several years before diagnosis. Due to lack of specific symptoms, endobronchial lipomas can be misdiagnosed as asthma, chronic bronchitis or chronic obstructive pulmonary disease¹.

Chest X-Ray shows hilar enlargement, atelectasis or pneumonia. Thoracic CT may reveal a low density mass located in main bronchus. The definite diagnosis is only obtained after biopsy performance during fiberoptic bronchoscopy, which is needed to exclude or confirm the presence of other pathology findings that would point to alternative diagnoses (e.g liposarcoma, hamartoma)^{9,10}.

The treatment options in endobronchial lipoma include bronchoscopic resection of the tumor, bronchotomy, lobectomy or pneumonectomy. The choice of approach depends on tumor size, location of the tumor and the degree of lung damage caused by the lesion^{1-3,7,8}. Recurrent rates are low. Surgical resection of the tumor is indicated when there is a possible co-existence of malignant neoplasm, or technical difficulties during bronchoscopic procedure. Ablative techniques can be used concomitantly with bronchoscopy and include yttrium aluminum garnet (YAG) laser, argon plasma coagulation of the base, cryotherapy, or ethanol ejection in the base.

CONCLUSION

Endobronchial lipoma is a rare, benign tumor, located in central airways, affecting middle-aged smokers, with male predominance. The co-existence with lung adenocarcinoma is infrequent.

It is noteworthy that detailed bronchoscopic evaluation is crucial, as we have observed lesions during bronchoscopy in different sites than those revealed in CT scan.

The bronchoscopic resection of endobronchial lipoma is the treatment of choice, because it is both diagnostic and therapeutic and is associated with less morbidity compared to surgical approach. Furthermore, bronchoscopy is not only less invasive method, but also preserves lung tissue, achieves good symptomatic control and local control and prevents from permanent lung damage.

ΠΕΡΙΛΗΨΗ

Συνύπαρξη ενδοβρογχικού λιπώματος και αδενοκαρκινώματος πνεύμονα

Βασιλική Πέττα¹, Αθανάσιος Ζέτος¹, Δανάη Μπισιρτζόγλου¹, Μαρία Σαλομίδου¹,

Γεώργιος Παπίας², Νίκη Αρνογιαννάκη², Χαράλαμπος Μαρκέτος¹

¹Πνευμονολογικό Τμήμα, ΓΑΟΝΑ "Ο Άγιος Σάββας", Αθήνα,

²Παθολογοανατομικό Τμήμα, ΓΑΟΝΑ "Ο Άγιος Σάββας", Αθήνα

Το ενδοβρογχικό λίπωμα είναι ένας σπάνιος καλοήθης όγκος με προέλευση από τον λιπώδη ιστό. Εμφανίζεται συχνότερα σε άνδρες καπνιστές μέσης ηλικίας, με υψηλότερη επίπτωση στην 5η και 6η δεκαετία της ζωής. Συχνά, ο όγκος εντοπίζεται σε κεντρικούς αεραγωγούς, σε λοβαίους ή τμηματικούς βρόγχους, κυρίως στον δεξιό πνεύμονα και αναδεικνύεται εύκολα κατά τη βρογχοσκόπηση. Η βλάβη μπορεί να οδηγήσει σε χρόνια καταστροφή του πνευμονικού παρεγχύματος, λόγω βρογχικής απόφραξης. Η βρογχοσκοπική εκτομή με λαβίδα ηλεκτροκαυτηρίας (snare) αποτελεί συγχρόνως διαγνωστική και θεραπευτική μέθοδο εκλογής. Ο καρκίνος πνεύμονα είναι η κύρια αιτία θανάτου παγκοσμίως και διαγιγνώσκεται σε προχωρημένα στάδια, λόγω απουσίας ειδικών συμπτωμάτων. Ο μη μικροκυτταρικός καρκίνος πνεύμονα ευθύνεται για το 80-85% των περιπτώσεων, με το αδενοκαρκίνωμα να αποτελεί τον πιο κοινό ιστολογικό τύπο. Σε αυτό το άρθρο παρουσιάζουμε μια σπάνια περίπτωση συνύπαρξης ενδοβρογχικού λιπώματος στον δεξιό πνεύμονα και αδενοκαρκινώματος στον αριστερό πνεύμονα σε 61χρονο άνδρα καπνιστή, χωρίς συμπτωματολογία.

Πνεύμων 2019, 32(3):101-104.

Λέξεις - Κλειδιά: Βρογχοσκόπηση, Μάζα, Ενδοβρογχικό λίπωμα, Βιοψία, Αδενοκαρκίνωμα πνεύμονα

REFERENCES

1. Sivapalan P, Gottlieb M, Christensen M, Clementsen PF. An obstructing endobronchial lipoma simulating COPD. *Eur Clin Respir J* 2014; 1. doi: 10.3402/ecrj.v1.25664. eCollection 2014.
2. Dy RV, Patel S, Harris K, Mador MJ. Endobronchial lipoma causing progressive dyspnea. *Respir Med Case Rep* 2017; 22:95-7.
3. Eren F, Candan T, Eren B, Comunoglu N, Comunoglu C. Endobronchial lipoma. *J Pak Med Assoc* 2013; 63:784-5.
4. Hirsch FR, Scagliotti GV, Mulshine JL, et al. Lung cancer: current therapies and new targeted treatments. *Lancet* 2017; 389(10066):299-311.
5. Laisaar T, Sarana B, Benno I, Laisaar KT. Surgically treated lung cancer patients: do they all smoke and would they all have been detected with lung cancer screening? *ERJ Open Res* 2018;4(3): pii: 00001-2018. doi: 10.1183/23120541.00001-2018.
6. Carbone DP, Gandara DR, Antonia SJ, Zielinski C, Paz-Ares L. Non-Small-Cell Lung Cancer: Role of the Immune System and Potential for Immunotherapy. *J Thorac Oncol* 2015;10:974-84.
7. Wang H, Du Z, Li A, Song J. Surgical treatment of an endobronchial lipoma obstructing the right upper bronchus: Imaging features with pathological correlation. *Pak J Med Sci* 2013; 29:1447-9.
8. Trivino A, Mora-Cabezas M, Vallejo-Benitez A, et al. Endobronchial lipoma: a rare cause of bronchial occlusion. *Arch Bronconeumol* 2013; 49:494-6.
9. Tronco Alves GR, Pasquali M, de Silva RV, Pereira Haygert CJ. An infrequent cause of persistent cough: endobronchial lipoma. *Ann Saudi Med* 2013; 33:636-7.
10. Iwabuchi H, Kamura T, Tanaka M, Kato H. A case of endobronchial lipoma. *Diagn Ther Endosc* 1999; 5:263-7.